

Giant cell arteritis

Karina Lazarewicz,¹ Pippa Watson²

¹Rheumatology, Manchester University Foundation Trust, Trafford Hospital

²Rheumatology, Manchester University Foundation Trust, Wythenshawe Hospital

Correspondence to: K Lazarewicz karinalazarewicz@yahoo.co.uk

Giant cell arteritis (GCA) is an inflammatory disease that affects medium and large blood vessels, classically the extracranial branches of the external carotid arteries. Inflammation in the wall of the affected artery may cause headache, scalp tenderness, jaw and tongue pain, and visual disturbances, but can also present with systemic or other less common symptoms, so that diagnosis can be challenging. It is a rare disease affecting 2.2 per 10 000 patient-years in the UK.¹

Consequences can be serious if the diagnosis is delayed, and may include visual loss, stroke, and aortic aneurysm. Many patients with GCA first present to their general practitioner or local emergency department. The most common presenting symptom of GCA is headache (76%)¹ but given its relative rarity, other causes of headache are much more common in these settings. Glucocorticosteroids are the mainstay of treatment, but at high doses and for prolonged periods of time are associated with substantial side effects. In April 2019, the National Institute for Health and Care Excellence (NICE) licensed tocilizumab for patients with refractory or relapsing disease.² This article provides a practical update for non-specialists with particular emphasis on making a diagnosis and initial management. It also discusses the new NICE guideline on tocilizumab and its likely impact.

WHAT YOU NEED TO KNOW

- Giant cell arteritis (GCA) is a medical emergency that requires immediate treatment with glucocorticosteroids
- Headache is the most common presenting symptom but is not always present
- Refer patients with suspected GCA and visual symptoms such as blurring, diplopia, or visual loss immediately to ophthalmology specialists, as untreated GCA with eye involvement can lead to loss of eyesight
- Refer patients without visual symptoms urgently to rheumatology specialists
- The mainstay of treatment is high dose prednisolone; in some patients with refractory or relapsing disease, tocilizumab can be added to prednisolone to treat GCA and act as a steroid sparing agent



0.5 HOURS



See <http://learning.bmj.com> for linked learning module

Presentation

Who gets it? GCA is relatively rare in a non-specialist setting, with an incidence of 7-29/100 000 population aged >50 in Europe.³ It is more prevalent in people of northern European ancestry.³ Frequency increases with age, being very rare in those under 50, with a mean age of onset of 70.⁴ As with many other autoimmune diseases, it is more common in women than men (2-6 times more likely).⁴

What causes it? Inflammation in the affected blood vessel wall, for example in the carotid artery and its branches, is characterised by the presence of macrophages (which may fuse to form the characteristic giant cells) and CD4+ T lymphocytes.⁵ This leads to thickening of the intima, and results in reduced blood flow and ischaemia, which is the main cause of pain in the areas that are supplied by the affected vessel (eg, temporal artery involvement can lead to headache). The release of cytokines leads to systemic symptoms.

Why does it matter? Early diagnosis and treatment of GCA can prevent development of serious complications, such as visual loss. Even when treated, visual loss can occur and be permanent. Before corticosteroid treatment was used to treat GCA, visual loss was noted in 30-60% of patients.⁶ If left untreated, up to half of individuals with GCA could sustain unilateral visual loss within days to weeks of symptoms.⁷

How do patients present? Symptoms and signs (table 1) frequently occur because of the involvement of arteries arising from the cranial branches of the aortic arch, particularly the extracranial branches of the carotid arteries (fig 1).

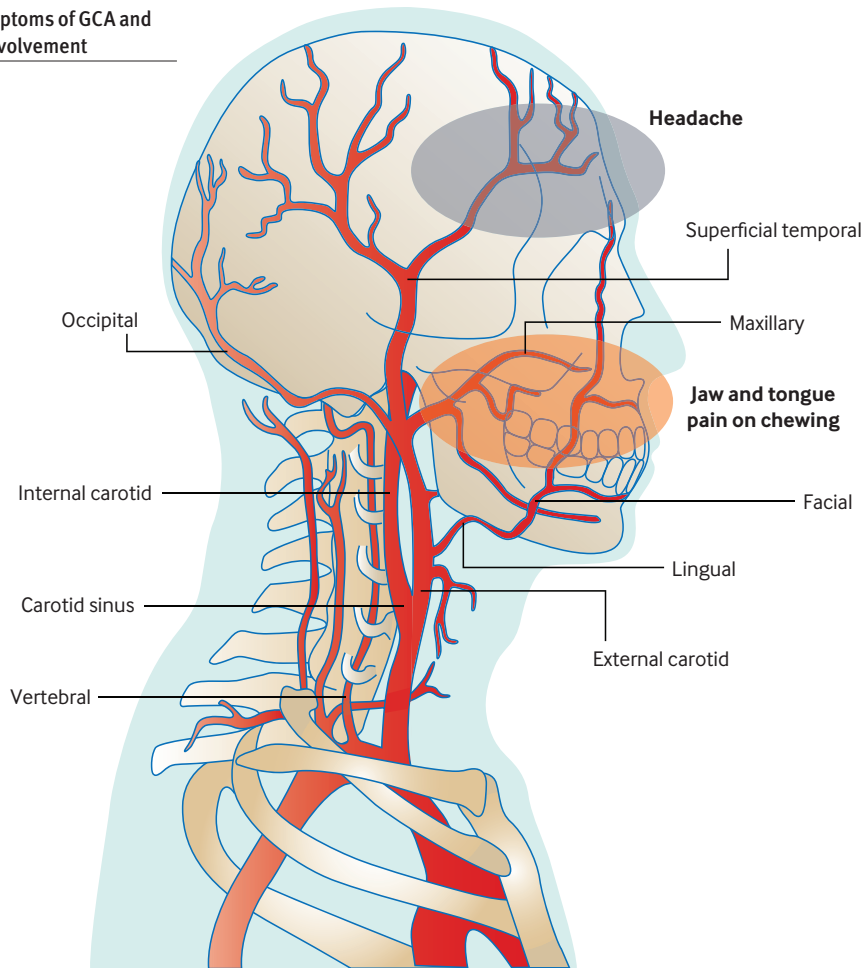
Table 1 | Clinical features associated with giant cell arteritis^{1,4}

| Symptoms/clinical features | Present at diagnosis (%) |
|----------------------------|--------------------------|
| Temporal headache | 52 |
| Jaw claudication | 34 |
| Scalp tenderness | 31 |
| Visual symptoms | 20-37 |
| Aortic aneurysm | 20 |
| Polymyalgia rheumatica | 40-60 |
| Constitutional symptoms | 30-60 |

HOW PATIENTS WERE INVOLVED IN THE CREATION OF THIS ARTICLE

We have discussed living with GCA with several of our patients. Our patients highlighted many important issues, including difficulty obtaining a diagnosis, and were extremely keen that we familiarise more doctors with the condition. They were unanimous about the need to improve diagnosis (such as by using ultrasound) and the side effect burden that is associated with long term glucocorticoid use. We have used this to inform the writing of our article.

Fig 1 | Symptoms of GCA and arterial involvement



EDUCATION INTO PRACTICE

- Would you consider GCA as a diagnosis in a patient who didn't present with a headache?
- Would you start glucocorticoid treatment before referral?
- Think about the last time you reviewed someone with GCA. Did you discuss potential steroid side effects and ways of minimising their impact? How might you do this more next time?

The American College of Rheumatology classification criteria¹⁵

At least three of five criteria must be present—sensitivity 93.5%, specificity 91.2%

- Age at onset >50
- New onset headache
- High erythrocyte sedimentation rate (>50 mm/hour by the Westergren method)
- Abnormal temporal artery on palpation
- Changes consistent with GCA on biopsy

Assessing a patient: history and examination

Ask about

Headache—this is the most common symptom, but it isn't always present. When present it is usually a severe temporal headache although GCA can present with occipital or parietal pain.⁸ It is quite often insidious in onset but can also be acute. The pain is described as dull in nature but this varies.

Visual symptoms—ask about visual symptoms in anyone presenting with a headache. Is there partial or complete loss of vision or diplopia? Ask specifically about both eyes. If a patient has unilateral eye involvement, the likelihood of the other eye being affected at the same time is 20-50%.⁹

Scalp tenderness—is there scalp tenderness when brushing hair?

Constitutional symptoms—fatigue, weight loss, anorexia, and sweats or fevers are frequently present. However, differential diagnoses, such as infection and malignancy, should also be considered.

Pain in the jaw on chewing (jaw claudication)—this is the most common

ischaemic complication. Usually pain happens after minutes of chewing over the masseter muscle, due to its ischaemia.¹⁰ Tongue claudication is very rarely the presenting symptom and is present in about 2-4% of patients.¹¹ Jaw (or tongue) claudication is associated with a high risk of ischaemic complications.¹²

Proximal muscle pain and stiffness—patients with coexisting polymyalgia rheumatica (PMR) may report muscle pain, particularly in the proximal arms and legs, and early morning stiffness usually lasting several hours. They often find it difficult to get out of bed in the morning.

Examine

Temporal arteries—palpate the temporal artery to look for tenderness, beading that feels like small hard lumps, and/or decreased or absent pulsation, for example by comparing it with the other side.

Vascular examination—look for large vessel vasculitis features such as bruits (eg, carotid or subclavian artery), decreased

arterial pulsation, or a blood pressure differential between arms.

Eyes—check visual acuity and visual fields, looking for anterior ischaemic optic neuropathy secondary to GCA, which may present as monocular loss of vision (over hours to days). Some patients report altitudinal vision loss (either lower or upper half of the visual field is selectively affected) or scotoma. Check pupillary reflexes for a relative afferent defect secondary to optic nerve ischaemia, and perform fundoscopy. Fundoscopy findings are not specific to GCA and may include cotton wool patches, oedema, pale discs, or even haemorrhage.

Scalp—feel for tenderness over the scalp; do not limit your examination only to the skin overlying the temporal artery as arteries supplying the scalp can also be involved.

Perform a thorough general examination, including (but not limited to) cardiovascular, respiratory, and abdominal systems to exclude other differential diagnoses (table 2).

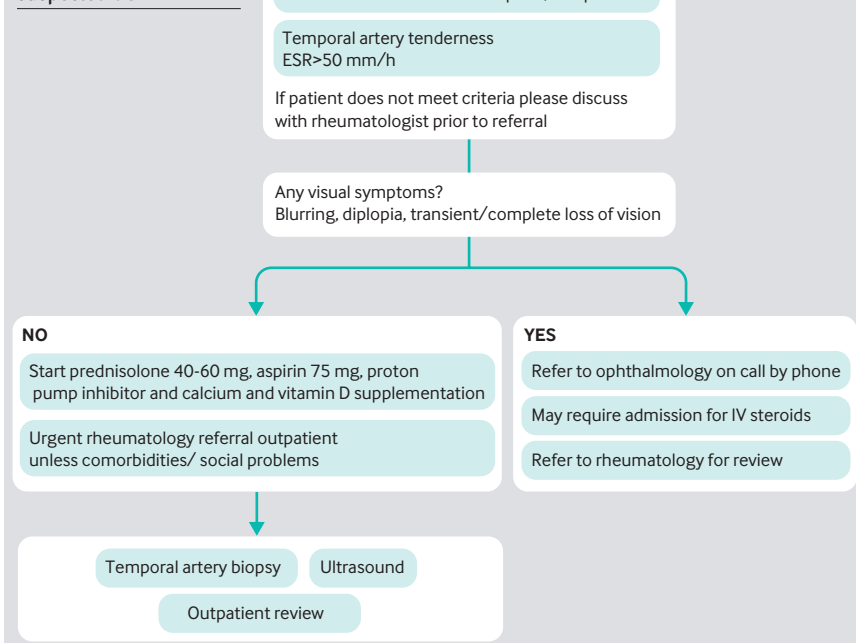
Table 2 | Differential diagnoses⁴⁻¹⁴

| Differential diagnoses | Features to consider |
|--|---|
| Headache | |
| Headache of other origin (cluster, migraine, tension, etc) | Recurrent attacks, visual aura, eye watering, nausea, photosensitivity |
| Sinusitis | Runny nose, nasal discharge, fever, pressure behind the eyes and cheeks |
| Trigeminal neuralgia | Severe shooting pain over the side of the face that may feel like an electric shock, burning pain |
| Ophthalmic varicella zoster infection (shingles) | Pain and burning over the distribution of temporal artery, sensitivity to touch, fever, itching, rash, blisters |
| Skull metastasis | Cranial nerve signs, eg, diplopia, localised pain and tenderness |
| High ESR/systemic features | |
| Polymyalgia rheumatica | Proximal muscle pain and stiffness especially in the morning (bilateral shoulder or pelvic girdle), increased inflammatory markers, extreme tiredness, loss of appetite, weight loss. Good response to steroids |
| Small/medium vessel vasculitis, eg, polyarteritis nodosa, granulomatosis with polyangiitis | Involvement of other systems, eg, ENT respiratory, renal involvement |
| Endocarditis | New or changing heart murmur, splenic tenderness, Janeway lesions, Osler's nodes, haematuria |
| Malignancy, eg, lung cancer | Smoking history, haemoptysis, shortness of breath, cough |
| Temporomandibular disorder | Localised pain on chewing, speaking, or yawning; immediate onset; dull aching pain |

Table 3 | Investigations to consider

| Investigation | Why |
|--|---|
| Full blood count, urea and electrolytes, liver function test, C-reactive protein (CRP), erythrocyte sedimentation rate (ESR) | ESR and CRP are usually elevated in patients with GCA. Only 4% have a normal ESR; 83% are above 50 mm/h ¹ Other typical findings include elevated alkaline phosphatase and thrombocytosis |
| Urine dipstick | Proteinuria or haematuria could indicate a small vessel vasculitis; haematuria could indicate endocarditis |
| Chest radiograph | Look for an aortic aneurysm Consider differential diagnoses such as lung cancer or small vessel vasculitis (looking for cavities) |
| CT head | Consider if predominant headache and atypical history |
| Temporal artery biopsy | Look for arteritis or atherosclerosis |
| Duplex ultrasonography | Look for hypoechoic "halo," occlusions, and stenosis |

Fig 2 | Example of local referral pathway for suspected GCA



Investigations

Recommended investigations are presented in table 3.

Classification

When classifying patients with vasculitis, the American College of Rheumatology criteria (box) may be helpful, but these are not diagnostic criteria, and should not be used as such. However, the criteria are straightforward to use and may help to start early treatment and trigger specialist referral.

Referral

Refer all patients with suspected GCA urgently to secondary care. If there is visual involvement refer immediately for ophthalmology review. Refer other cases urgently for rheumatology outpatient review to be seen as soon as possible, usually within two weeks. Commence glucocorticosteroids in primary care as soon as the diagnosis is suspected. Many specialist centres have a fast track GCA pathway (fig 2), which is likely to include prompt review, temporal artery biopsy, with or without ultrasound. Be aware of your local arrangements and discuss atypical cases early with your local specialist.

Temporal artery biopsy is currently the gold standard for diagnosis in all patients with suspected GCA. According to the 2010 British Society of Rheumatology guidelines for the management of GCA, a unilateral biopsy of at least 1 cm should be done in an experienced surgical unit. The procedure is usually carried out under local anaesthesia. A positive result means that inflammatory changes are confirmed. According to American College of Rheumatology 1990 criteria for classification of GCA, the specificity of temporal artery biopsy is 73.1% and sensitivity is 92.9%. Do not delay steroid treatment waiting for the results as the diagnosis of GCA is mainly based on clinical judgment, and even with a negative biopsy a patient can still have GCA. Biopsy remains positive for 2-6 weeks after commencing steroids, although the sooner the biopsy is performed the greater the chance of it being positive.¹⁶ One of the biggest challenges is the high false negative rate due in part to the presence of skip lesions.

Ultrasound is increasingly being introduced as part of the assessment of patients with suspected GCA, to visualise temporal and axillary arteries. Typical findings include a halo suggestive of vessel wall oedema. Monti et al¹⁷ found that ultrasound had a sensitivity of 63% and specificity of 100% in routine clinical practice. Introduction of this technique in their centre led to a decrease in their biopsy rate from 42% to 24%. Other techniques, such as F-18 FDG-PET/CT, are particularly useful in cases where there are systemic but no localising features.